

DOUBLE LOCK TWIN FORCE BITE CORRECTOR

Light Force and Patient Friendly!

By Dr. Maurice C. Corbett, D.D.S.



It has been noted that the skeletal goal of orthodontics is a balanced maxillo-mandibular relationship from which all the other goals can be achieved. These other goals include acceptable esthetics, proper dental relationships, balanced functional aspects, good periodontal condition, and stability. The skeletal relationship must be such that when, or after, the teeth are positioned correctly within the maxilla and the mandible, these goals can be met; otherwise some skeletal modification or orthognathic surgery must be included in the treatment plan.

Pancherez and Ruf and others state that growth adaptation treatment with removable appliances is only successful during the main growth period around puberty. Whereas, fixed appliances can change mandibular growth to a clinical degree and make significant dental alveolar changes. These studies show that Class II malocclusions can be corrected post-pubertal, with fixed appliances. Temporo-mandibular joints reveal condylar and glenoid fossa remodeling and do not result in temporo-mandibular dysfunction on a long term basis. Therefore, this treatment could be an alternative to orthognathic surgery in some cases.

Orthopedic mandibular body repositioning of up to 3 millimeters has been noted following palatal expansion and molar rotation.

In addition, it is postulated that the mandible has certain genetic potential, and with the relief of inhibitory forces, this genetic potential can be achieved. Thus, by establishing the appropriate arch width, removal of occlusal interferences, and abhorrent functional forces, this growth potential can be realized.

Whether this growth realization is enough to achieve the needed mandibular position, or surgical assistance is required, will depend on the individual case. A comprehensive diagnosis and treatment plan is necessary to select the mechanics to achieve the goals of treatment.

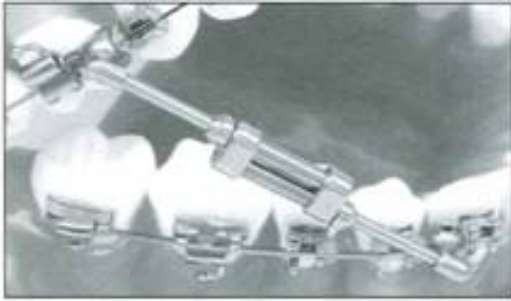

Fig. 1

The TWIN FORCE@ Bite Corrector (Fig. 1) was developed to increase the condylar cartilage growth rate without immobilizing the mandible in a protruded position and deliver a light continuous force that:

- Will allow a full range of excursive movements of the mandible
- Will not produce compressive forces to the temporo-mandibular fossa
- Will not extrude the maxillary anterior teeth
- Will intrude the maxillary molar
- Will intrude the mandibular incisors
- Minimize backward rotation of the mandible
- Avoid undo labial tipping of the mandibular incisors
- Will not extrude the mandibular molar
- Minimize maxillary molar tipping
- Aid in midline correction.

In the short term, do not expect orthopedic effects from the TWIN FORCE@ Bite Corrector. Skeletal changes require long term retention of remodeling changes in the glenoid fossa and the condyle with a stabilized neuromuscular occlusion to avoid compressive forces acting on the temporo-mandibular fossa.

TWIN FORCE® BITE CORRECTOR DESIGN

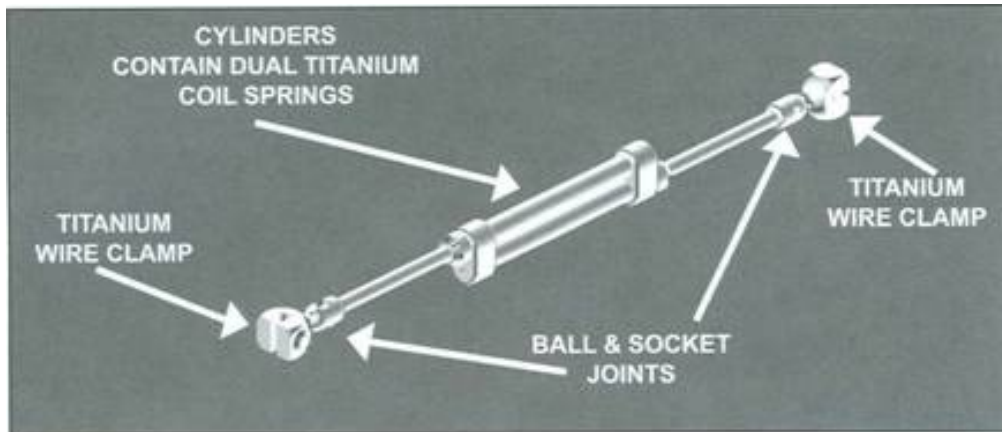


Fig. 2

The TWIN FORCE® Bite Corrector (Fig. 2) is an appliance designed with dual plungers to collectively provide a continuous light force (200-225 grams).

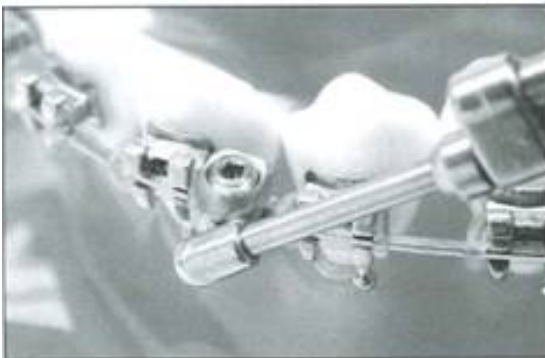


Fig. 3

Installation is easy. The appliance attaches to the upper and lower archwires with a ball and socket wire clamp. No laboratory work is required.

The TWIN FORCE® Bite Corrector will fit either the right or left sides and may be used for both Class II and Class III correction. Two sizes are available for non-extraction and mixed dentition cases as well as extraction cases. Ball joints provide lateral flexibility and full mandibular movement.

CASE PREPARATION

Following a comprehensive diagnosis and treatment plan, including a neuromuscular mandibular position evaluation, the arches are banded and bracketed with double buccal tubes on the maxillary first molar bands, and lingual sheaths for optional use of transpalatal bar or rotator as required for expansion or constriction. The maxillary and mandibular dentitions should be aligned, leveled, and overbite corrected to a normal position to their respective skeletal bases and engaged with a flat rectangular stainless steel archwire.

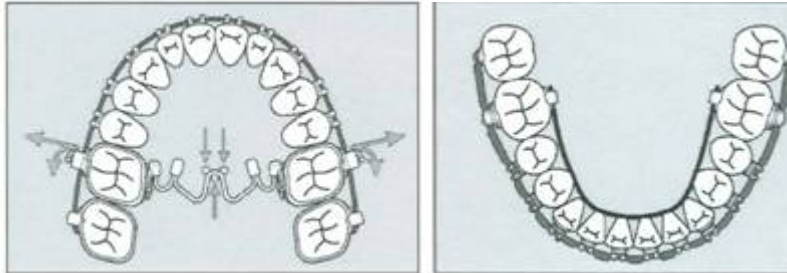


Fig. 4

Frequently asked questions are:

1. When do I use the TWIN FORCE® Bite Corrector?
During intermediate stage of treatment, when both arches are leveled.
2. What archwire should I use?
Level to a Rectangular S.S. .017x.025 (.018 slot) and .018x.025 (.022 slot) minimum, this will help prevent intrusion.
3. What size do I use?
Measurement for Double Lock: measure from mesial of upper molar tube to distal of lower cuspid: (Fig. 5)



Fig. 5
27mm + use standard version.

Less than 27mm use small version.

APPLIANCE PLACEMENT

STEP 1. Stabilization of the lower arch can be enhanced by the placement of a fixed lingual arch and figure 8 tying under the archwire with wire ligature, cinch back and single tie the brackets. (Fig. 6)



Fig. 6

STEP 2. The maxillary rectangular wire should have compensating curve for bite opening and cinched back and/or elastic power chain second bicuspid to second bicuspid.

STEP 3. With the mouth wide open, place and tighten the archwire clamp of the TWIN FORCE® Bite Corrector with the straight end of the locking wrench, between the maxillary first molars and second bicuspids, then securely tighten clamp with the right angle end of the wrench. (Fig. 7)

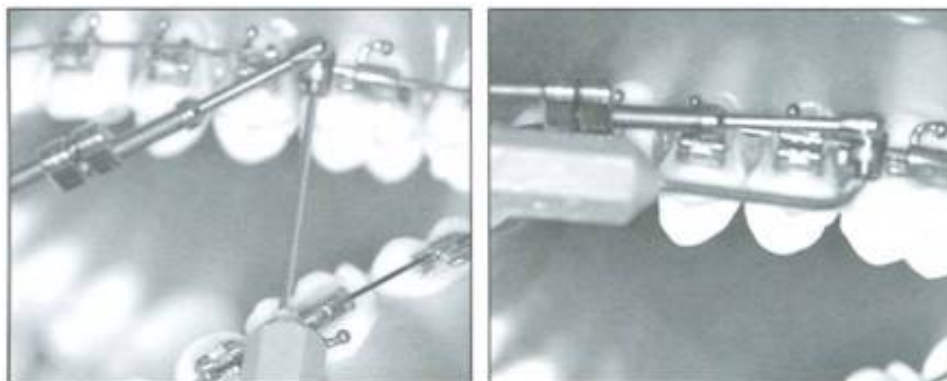


Fig. 7

STEP 4. Place the archwire clamp of the TWIN FORCE® Bite Corrector between the mandibular first bicuspid and the cuspids and tighten with the straight end of the locking wrench. (Fig. 8)

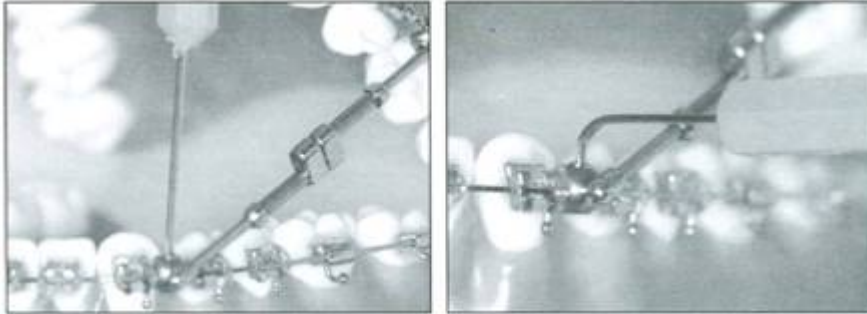


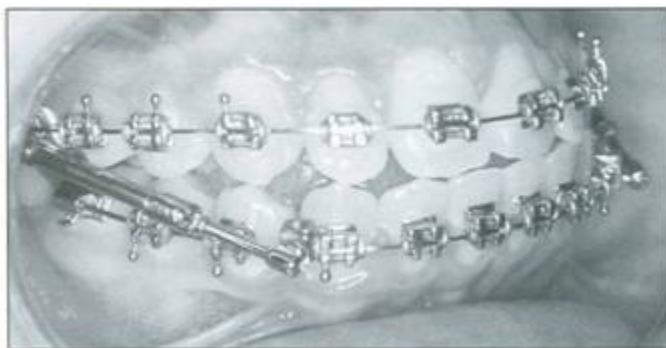Fig. 8

STEP 5. Mandibular advancement should be in a range of Class I and edge to edge. (Fig. 9) Check the patient with the mouth open, closed, and with lateral excursions for any interference and adjust if necessary. Have the patient chew 1/2 piece of flat sugarless gum to demonstrate that jaw movement and eating can be normal.

See the video at:

<http://www.orthodonticsupplies.com.au/twin-force-bite-corrector.html>

A soft diet is recommended for the first several days and a prophylactic pain reliever such as Acetaminophen or Ibuprofen may be used for discomfort.



MAINTENANCE

1. See the patient for observation in one week and then every 4-6 weeks thereafter.
2. Be sure to avoid spacing of the teeth with ligature ties and cinch backs.
3. You may expect approximately 1.0 millimeters of dento-alveolar changes per month in the late mixed dentition or early permanent dentition.
4. Orthopedic changes are minimal and usually the result of mandibular adjustment to expansion and arch width co-ordination. Long term retention may stabilize changes in the glenoid fossa and condyle.
5. Watch, adjust, and overcorrect for midline correction.

TREATMENT COMPLETION

The TWIN FORCE® Bite Corrector should be maintained in place one month for each millimeter of correction with a minimum of three months. The appliance is then removed and box, short Class II or Class III elastics are worn as needed to settle the inter-cuspal contact. (Fig. 10) Normal finishing procedures are then followed to establish a neuromuscularly balanced occlusion. (Fig. 11)

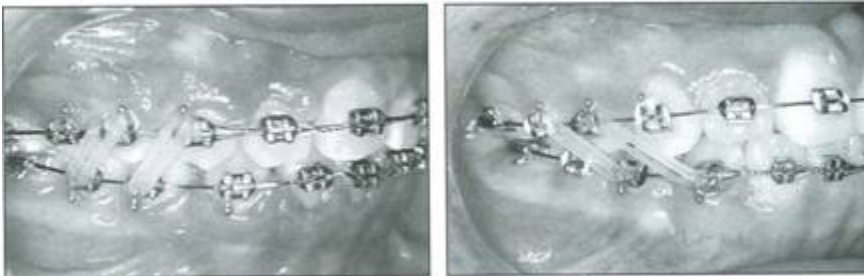
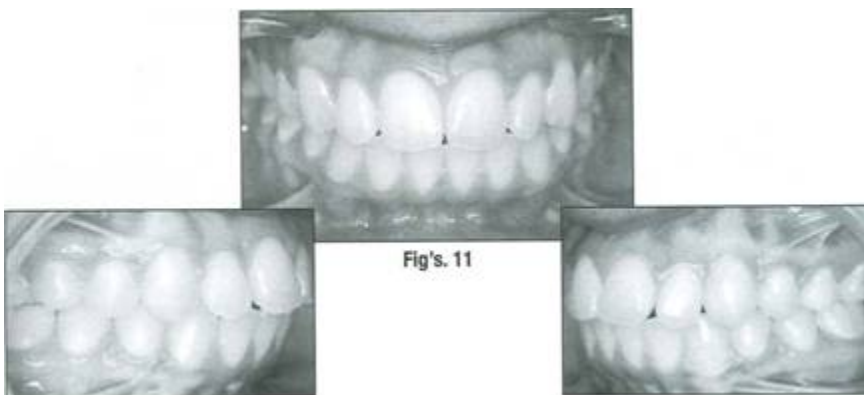

Fig. 10



RETENTION

Retention appliances should be designed to maintain the mandibular position for longer stability. Remember that the short term goals are achieved by dental alveolar changes and the modifications within the glenoid fossa and the condyle are most likely dependent on long term retention and the maintenance of the neuro-muscularly balanced buccal occlusion.

CLASS II CORRECTION

1. Place the archwire clamp mesial to the mandibular first molar tube from the occlusal and secure. Place and secure the archwire clamp distal to the maxillary cuspid bracket from the occlusal. (Fig. 12)
2. Monitor for molar and anterior intrusion and/or flaring of the incisors. At times it may be necessary to use anterior elastics to prevent the bite from opening.

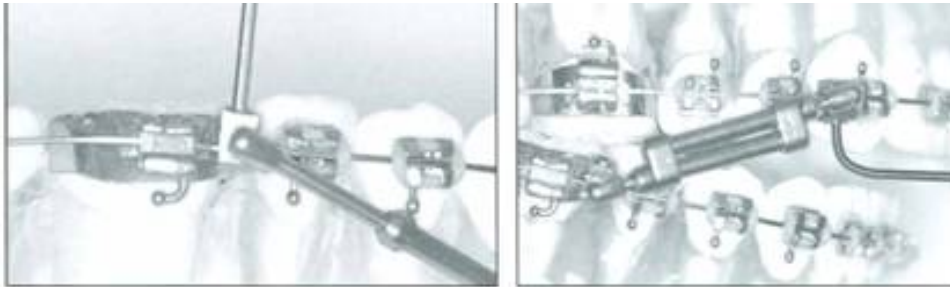
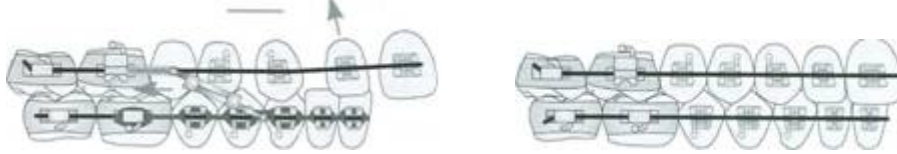

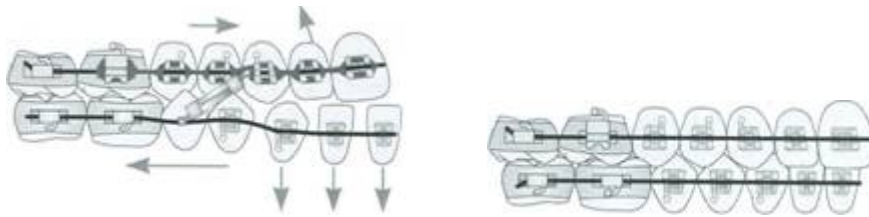
Fig. 12

ALTERNATIVE USES OF THE TWIN FORCE@ DOUBLE LOCK APPLIANCE

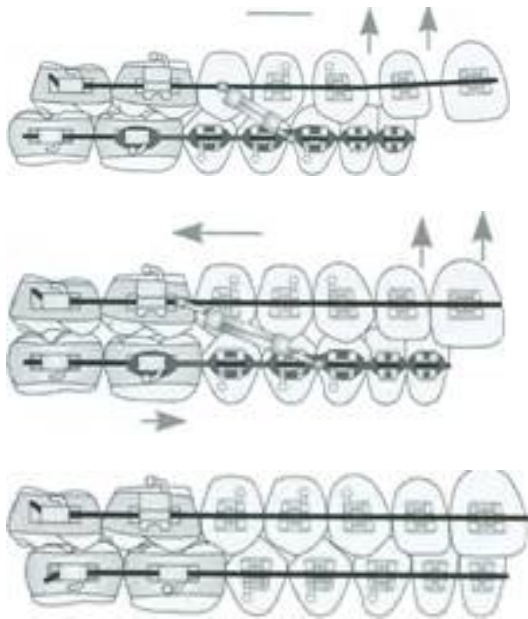
Class I Flared Maxillary Incisors



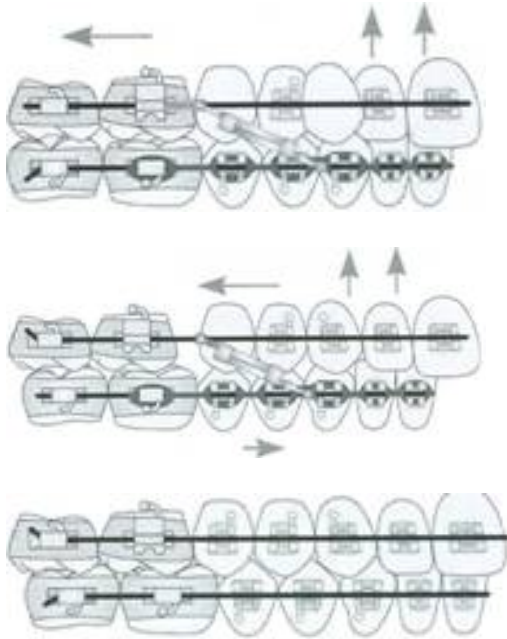
Class I Flared Mandibular Incisors



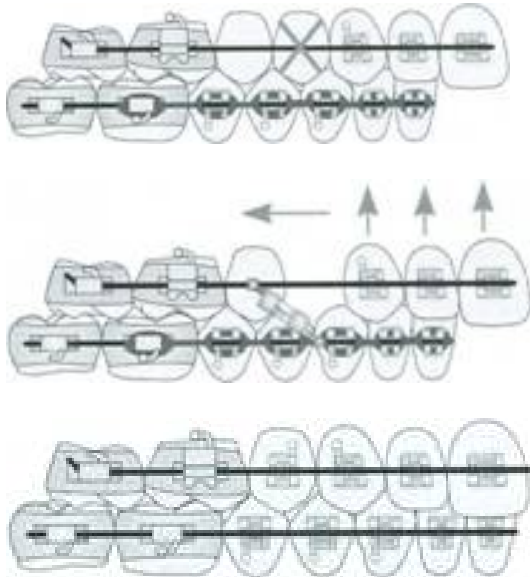
Class II Div. 1 Flared Maxillary Incisors



Class II Blocked Out Canine



Class II Maxillary Procumbancy



REFERENCES

1. Corbett, Maurice C., Treatment Goals Should Be Established Before Treatment Begins, WireLine, Spring 1998.
2. McNamara, J. A., Jr. Components of Class II malocclusion in children 8-10 years of age, Angle Orthod. 51:177-202.
3. Enlow, Donald H., Handbook of Facial Growth, W.B. Saunders 1982
4. Graber, Thomas Moo Rakose, Thomas, Petrovic, Alexandre, Dentofacial Orthopedics With Functional Appliances, C. V. Mosby 1985
5. White, LW, Current Herbst Appliance Therapy, J. Clin. Orthod. 23:269-309, 1994
6. Jasper, J.J., and McNamara, J.A., Jr. The Correction of inter-arch malocclusions using a fixed force module, Am. J. Orthod. 108:641-650, 1995
7. Ruf, Sabine, and Pancherz, Hans, temporo-mandibular joint remodeling in adolescents and young adults during Herbst treatment: A prospective longitudinal magnetic resonance imaging and cephalometric radiographic investigation, Am J. Orthod. Dentofacial Orthop. 1999; 115:607-18)
8. Devincenzo, John, The Eureka Spring: A new interarch force delivery system, J. Clin. Orthod. July 1997 (454-467)
9. Voudouris, J.C. and Kuflinec, M.M., Improved Clinical use of IWin-block and Herbst as a result of radiating viscoelastic tissue forces on the condyle and fossa in treatment and long-term retention: Growth relativity, Am. J. Orthod. 117:247-266, 2000
10. Pancherz, Hans, Dentofacial orthopedics or orthognathic surgery: Is it a matter of age? American Journal of Orthodontics and Dentofacial Orthopedics: 2000:117:571-74.
11. Pancherz H, Ruf, S. Thomalske-Faubert, C., Mandibular articular disk position changes during Herbst treatment: A prospective longitudinal MRI study, American Journal of Orthodontics and Dentofacial Orthopedics 1999;116:207-14.
12. Ruf, S. Pancherz, H., Long-term TMJ effects of Herbst treatment: A clinical and MRI study, American Journal of Orthodontics and Dentofacial Orthopedics: 1998; 114:475-83.

13. Ruf, S. Pancherz, H., Dentoskeletal effects and facial profile changes in young adults treated with the Herbst appliance, Angle Orthodontics 1999;69:239-46.
14. Ruf, S. Pancherz, H., Does Bite-Jumping Damage the TMJ? A Prospective Longitudinal Clinical and MRI study of Herbst Patients, Angle Orthodontics 2000;70: 183-99.
15. McNamara, J.A., Jr. and Brudon, w.L., Orthodontic and Orthopedic Treatment in the Mixed Dentition, Needham Press 1995
16. Corbett, Maurice C., Slow and Continuous Maxillary Expansion, Molar Rotation, and Molar Distalization, J. Clin. Orthod. April 1997(253-263)

Ortho Organizers Pty Ltd

PO Box 478
Sylvania Southgate NSW 2224
Australia

1300 ORDERZ

(1300 673 379)

www.naol.com.au

sales@naol.com.au