

REPRINTED FROM
JOURNAL OF CLINICAL ORTHODONTICS
1828 PEARL STREET, BOULDER, COLORADO 80302



Dr. Corbett is in the private practice of orthodontics at
1 E. Carmel Valley Road, Carmel Valley, CA 93924.

Slow and Continuous Maxillary Expansion, Molar Rotation, and Molar Distalization

MAURICE C. CORBETT, DDS

An estimated 25-30% of all orthodontic patients can benefit from maxillary expansion, and 95% of Class II cases can be improved by molar rotation, distalization, and expansion. Rapid palatal expanders such as the Haas and the Hyrax have traditionally been used for treating transverse maxillary discrepancies, but these appliances will not rotate or distalize molars.

Furthermore, rapid palatal expansion has been shown to produce forces ranging from 3 to more than 20 pounds. Studies have documented free-floating bone fragments, bleeding, micro-fractures, cyst formation, vascular disorganization, and connective tissue inflammation in suture sites during rapid expansion.

Story and Ekstrom have suggested that slow expansion procedures allow physiologic adjustments and reconstitution of the sutural elements over a period of about 30 days. McAndrews demonstrated that the application of light, continuous forces in areas of periosteal growth allows normal arch dimensions to develop at any age without undue tipping of the abutment teeth. Increased fibroblastic, osteoclastic, and osteoblastic activity seems to occur when the maxilla is widened slowly. Slower expansion has also been associated with more physiologic stability and less potential for relapse than with rapid expansion. The neuromuscular adaptation of the mandible to the maxilla in slow expansion allows a normal vertical closure.

This article will introduce a fixed-removable nickel titanium appliance, the Nitanium Palatal Expander2* (Fig. 1), that delivers a uniform, slow, continuous force for maxillary expansion, molar rotation and distalization, and arch development. This appliance expands at a rate that maintains tissue integrity during repositioning and remodeling of the teeth and bone. In other words, as the palate expands, regeneration matches the rate of expansion.

The action of the NPE2 is made possible by harnessing nickel titanium's properties of shape memory and transition temperature. Shape memory is the ability to constantly return to a set shape after deformation. Nickel titanium can be alloyed to produce a metal with a specific thermal transition temperature in the case of the NPE2, 94°F. At temperatures higher than the transition temperature, interatomic forces bind the atoms more tightly, producing a stiffer metal. At lower temperatures, the forces weaken, making the metal quite flexible.

***Nitanium is a registered trademark and Palatal Expander2 and Molar Rotator2 are trademarks of Ortho Organizers, Inc., 1619 S. Rancho Santa Fe Road, San Marcos, CA 92069.**

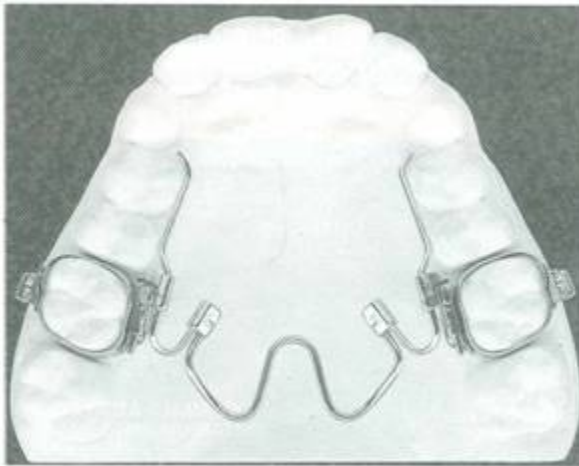


Fig. 1 Nitanium Palatal Expander2.

The NPE2 delivers a force of 350g in 3mm increments. If a 4mm expansion appliance is placed, the force will initially be higher, but will return to 350g once 3mm of expansion has occurred. Because the force application is preprogrammed, it is self-limiting. Nevertheless, slight adjustments can be made by the clinician at any time to constrict the appliance or add further expansion.

Appliance Design and Selection

The NPE2 incorporates an innovative lingual attachment with .036" Ortholoy arms and molar loops for unilateral and bilateral adjustments (Fig. 2). A locking indentation in the lingual attachment fastens the appliance securely to the maxillary molar band. To prevent removal or accidental dislodging, the appliance should also be tied in with ligatures.

The vast majority of palatal expansion patients need at least 4mm of expansion at the maxillary first molars (2mm per side). An additional 2-3mm can be gained by adjusting the palatal Nitanium loop of the NPE2. If more than 8mm of expansion is needed, two separate expanders may need to be used in sequence. If the molars are too severely rotated to place an expander, a Nitanium Molar Rotator² should be used prior to the NPE2.

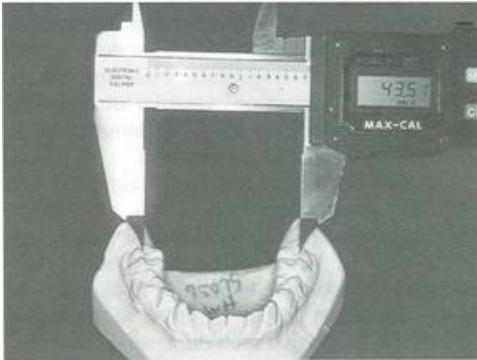


Fig. 3 Mandibular arch width measured between tips of distobuccal first molar cusps.

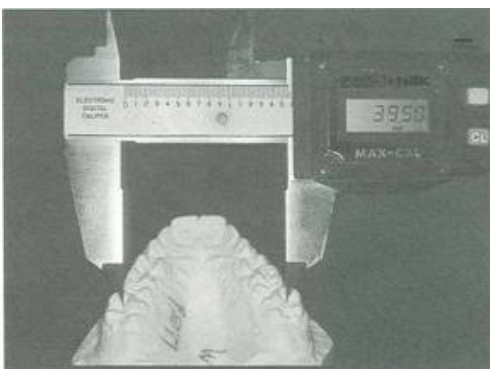


Fig. 4 Maxillary arch width measured between central pits of first molars.

The NPE2 is available in 10 sizes, from 26mm to 44mm in 2mm increments. The size of the expander is selected by one of the following two methods:

1. With the patient's mandibular first molars in normal position, measure the arch width between the tips of the right and left distobuccal cusps (Fig. 3). Now measure the arch width between the central pits of the maxillary right and left first molars (Fig. 4). The difference between these two measurements is the amount of expansion required. Measure the distance between the right and left maxillary first molars from the lingual surfaces where the sheaths will be placed (Fig. 5). Add this value to the required expansion. The total will indicate the size of NPE2 to use, allowing for the prescribed expansion plus 1.5-2mm of overcorrection to compensate for the combined width of the band material, cement, and lingual sheaths.
2. Measure across the mandibular arch between the central pits of the first molars (Fig. 6), then subtract 4mm to determine the size of NPE2 to use.

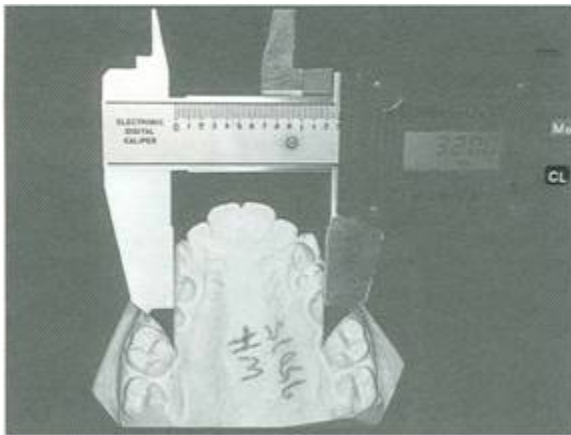


Fig. 5 Mandibular arch width measured between sites of lingual sheaths.

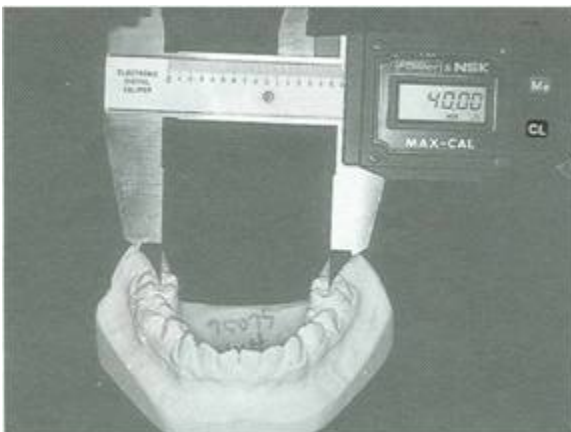


Fig. 6 Mandibular arch width measured between central pits of first molars.

Appliance Preparation and Placement

1. After adequate separation, fit and place bands, with lingual sheaths attached, on the maxillary first molars.
2. Remove the bands, and assemble the NPE2 and the bands as one passive unit, securing the appliance to the bands with ligature wire (Fig. 7).
3. For patient education or for adjustment of the Ortholoy wire, the molar loops, or the Nitanium wire, a trial fitting can be done prior to cementation. Modifications of 1-2mm can be made to the Nitanium wire to increase or decrease the amount of expansion, and individual adjustments to the molar loops can be made as needed (Fig. 8).
4. For best results, use a triple-cure glass ionomer cement. Mix the cement, place the cement in the bands, and spray the entire surface of the Nitanium wire with a tetrafluoroethane refrigerant spray, which will make the appliance dead soft for easy placement (Fig. 9).



Fig. 7 NPE2 tied to molar band with ligature wire.

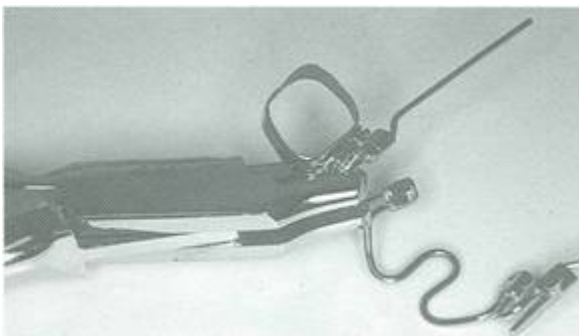


Fig. 8 Molar loop adjusted with plier.

5. Seat one band completely, then seat the other band. Immediately cure the cement for 15 seconds per side initially, then for an additional 25 seconds per side to ensure a complete set (Fig. 10).

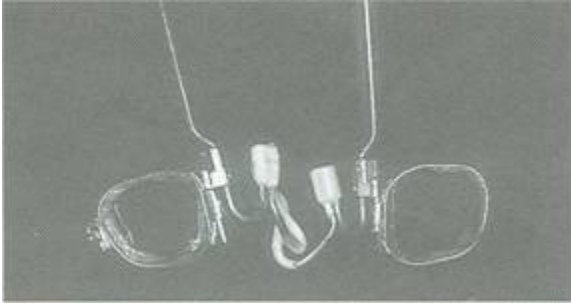


Fig. 9 Titanium wire softened with refrigerant spray for placement.

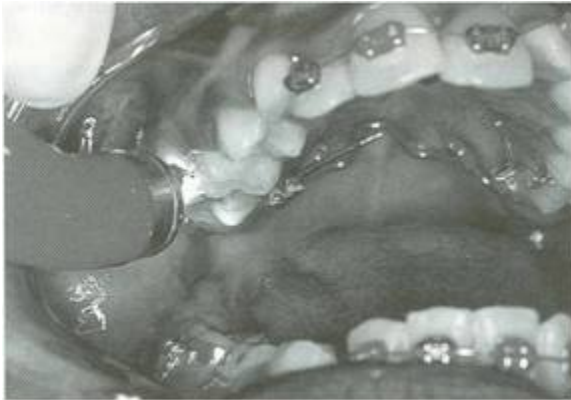

Fig. 10 Light-curing of cement.

As the mouth begins to warm the nickel titanium, the wire will stiffen, and the shape memory will be restored. The expander will begin to exert a low, continuous force against the teeth and the midpalatal suture (Fig. 11). The patient should be instructed to sip a cold fluid as needed to relieve the slight pressure. Do not use an appliance that expands more than 4mm at one time, because with the molar bands and sheaths, the expansion will actually be about 6mm.

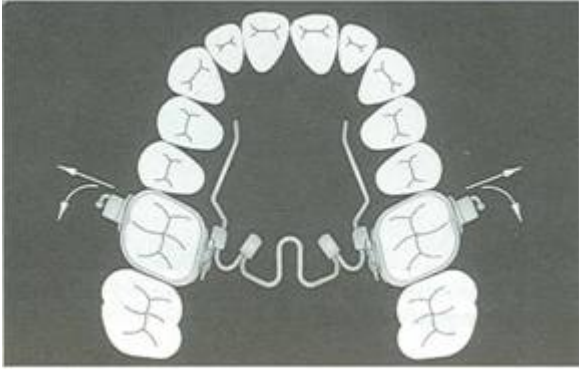


Fig. 11 NPE2 after initial placement.

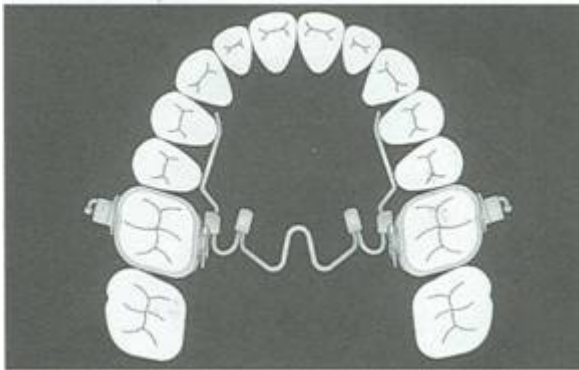


Fig. 12 NPE2 as passive retainer after completion of expansion.

TABLE 1 USUAL LENGTH OF TREATMENT (MONTHS)

	Expansion	Retention
Primary Dentition	1-2 (sometimes less)	2
Mixed Dentition	2-3 (depending on severity)	2
Young Adults	3	2
Adults	5 or more (depending on age)	3

Expansion is normally completed in two to four months (Table 1). The appliance should then be left in place for two to three months of passive retention (Fig. 12).

CASE 1

An 11-year-old female presented with maxillary constriction and a Class II, subdivision right malocclusion with a mesially rotated maxillary right first molar. She had retained primary teeth, an ectopically erupting maxillary cuspid, and an open bite (Fig. 13).

Measuring the arch as described above indicated a need for 4mm of palatal expansion and a size 36 NPE2, with additional rotation placed in the molar loop on the maxillary right side (Fig. 14).

The desired expansion was achieved in less than three months (Fig. 15). The appliance was left in place for another three months of retention and tooth eruption, after which the patient was scheduled for full fixed appliance therapy for final detailing (Fig. 16). The palatal expansion occurred without anterior spacing and without undue separation of the bony segments, allowing osteoblastic activity to keep up with sutural remodeling.

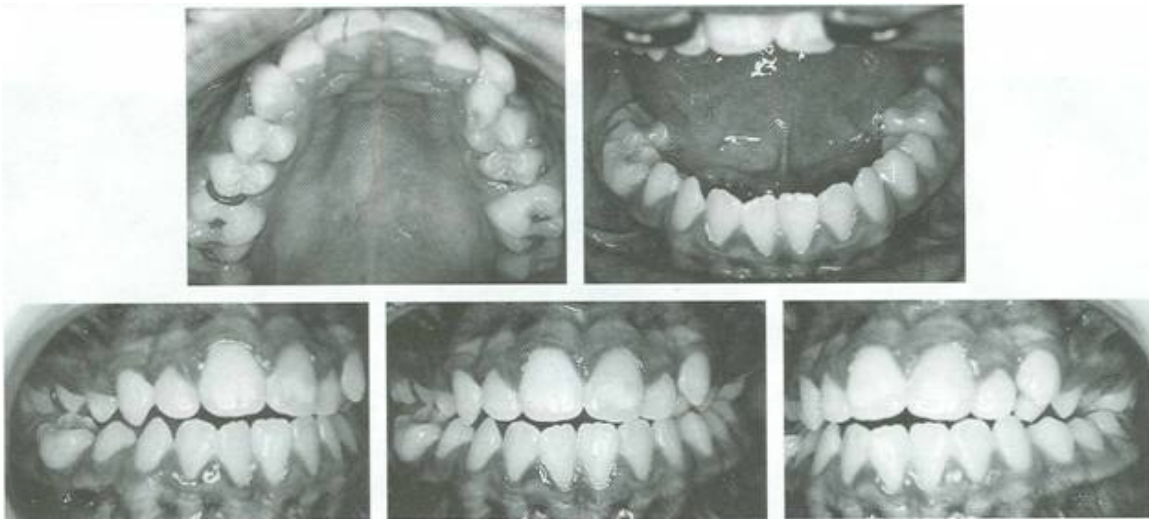


Fig. 13 Case 1. 11-year-old female before treatment.

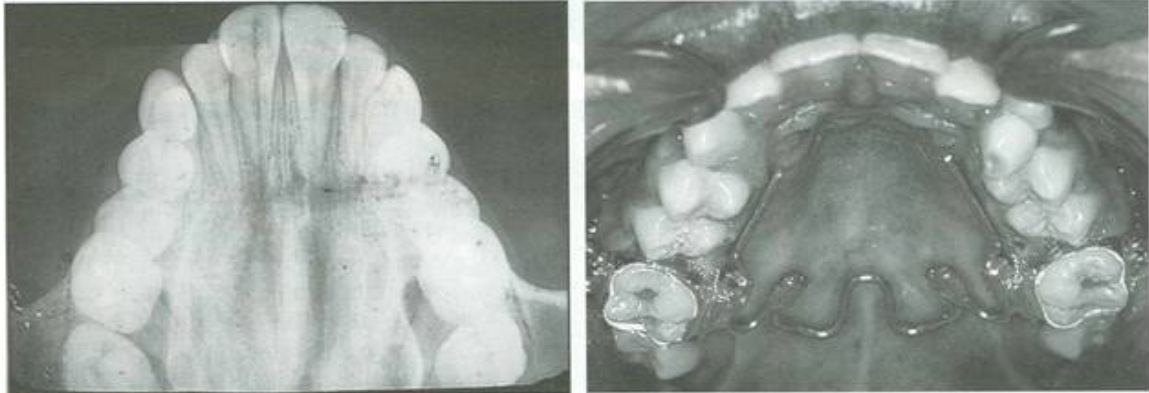


Fig. 14 Case 1. Palatal x-ray and NPE2 at initial placement.

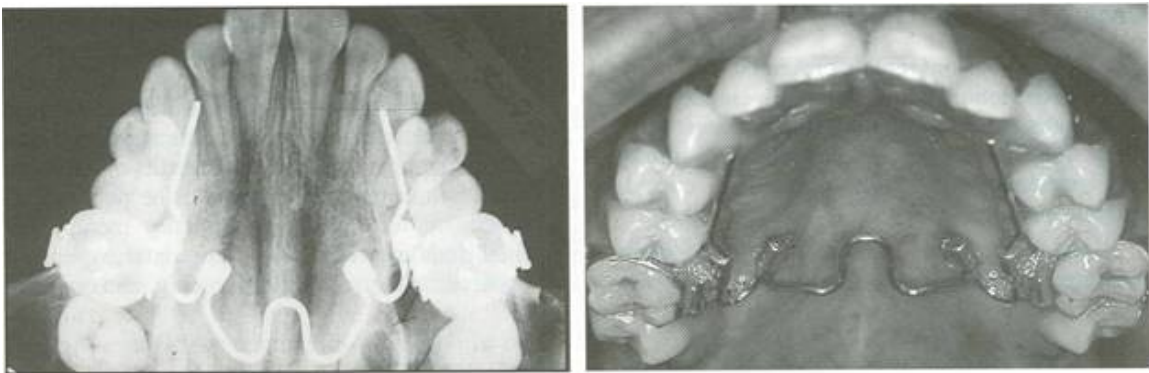


Fig. 15 Case 1. After three months of expansion.

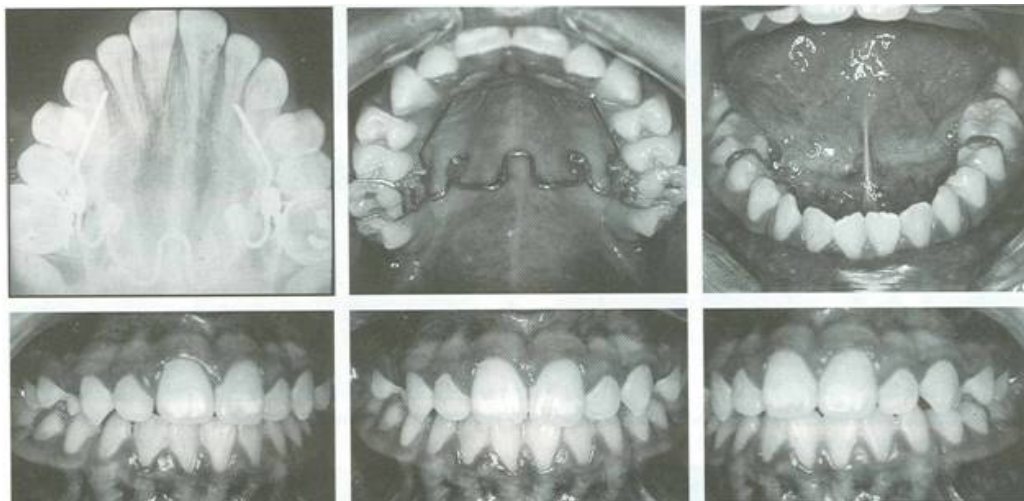


Fig. 16 Case 1. After three months of passive retention.

CASE 2

A 10-year-old female presented with a Class I malocclusion with maxillary constriction, an open bite, and a fingersucking habit (Fig. 17).

She needed 4mm of expansion and a size 34 NPE2 (Fig. 18). First-phase treatment objectives of expanded archform, space for cuspid eruption, and bite closure were achieved in four months (Fig. 19). The appliance was removed, and the case was allowed to settle with a Nance button retainer until full eruption, when detailing will be completed. The NPE2 could have been left passively in place to help intrude the molars and close the bite. X-rays showed an expanded palate with the suture intact and minimal tipping.

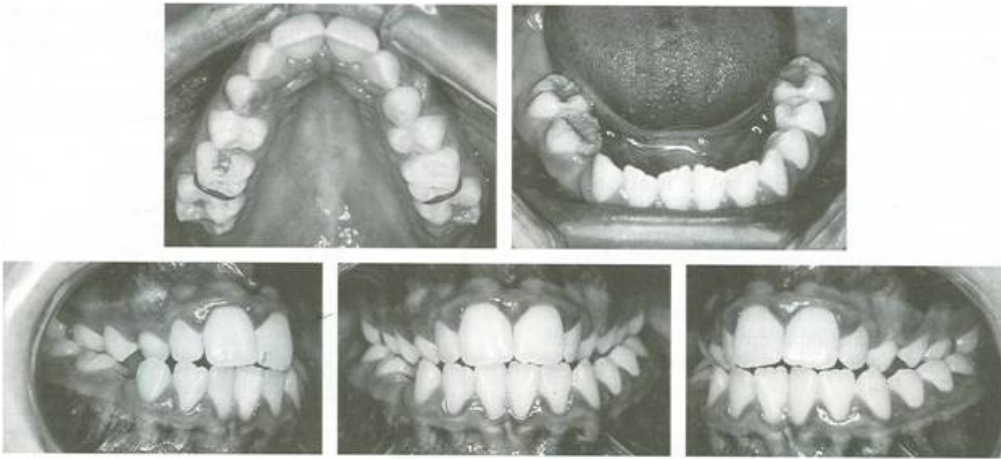


Fig. 17 Case 2. 10-year-old female before treatment.

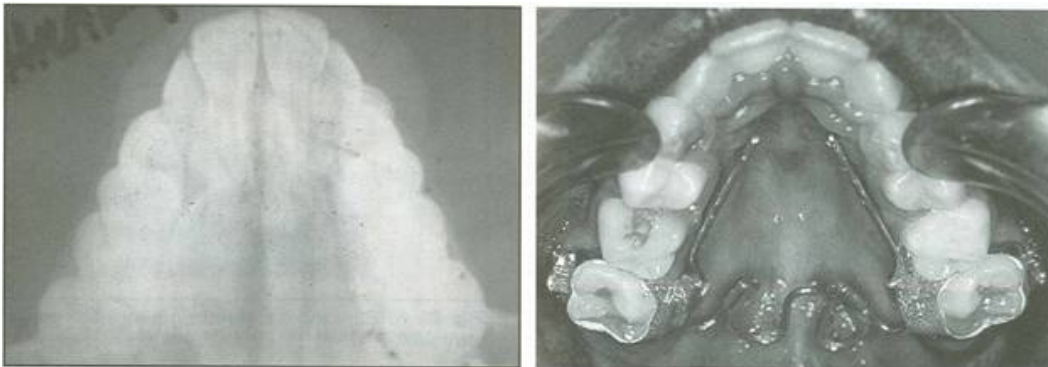


Fig. 18 Case 2. Palatal x-ray and NPE2 at initial placement.

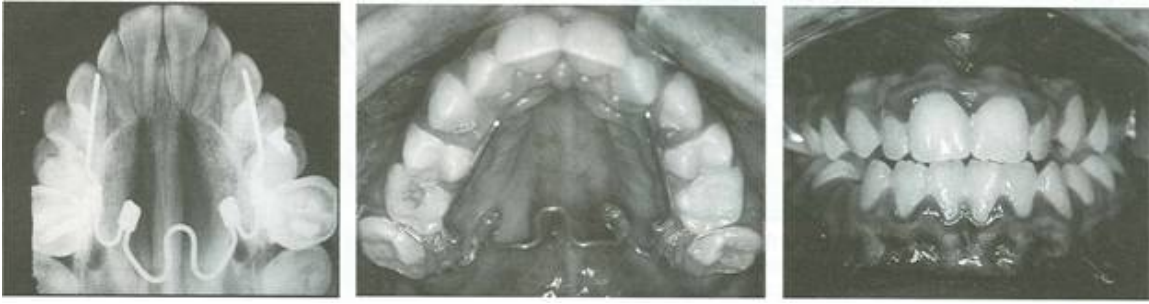

Fig. 19 Case 2. After four months of expansion.

Additional Functions of the NPE2

When the NPE2 is first placed, the Orthology arms will not contact the bicuspids (Fig. 20A). As soon as the molars rotate, move distally 1-3mm, and expand, the arms will touch the bicuspids (Fig. 20B). The appliance initially appears to move palatally, but as it expands, it will move occlusally. This will produce a lower tongue posture that can promote expansion and transverse growth in the mandibular arch (Fig. 21).

The NPE2 also frees the growth restriction of posterior functional crossbite and provides space for impacted canines. At first, the movement will be orthodontic, but after expansion of the molars is achieved, there will be orthopedic changes in the maxilla and often mandibular repositioning as well.

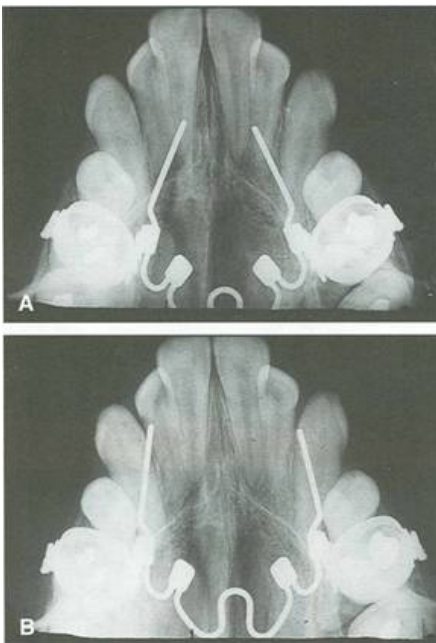


Fig. 20 A. Orthology arms do not contact bicuspids at initial placement. B. After molar expansion, distal rotation, and distalization, Orthology arms contact bicuspids.

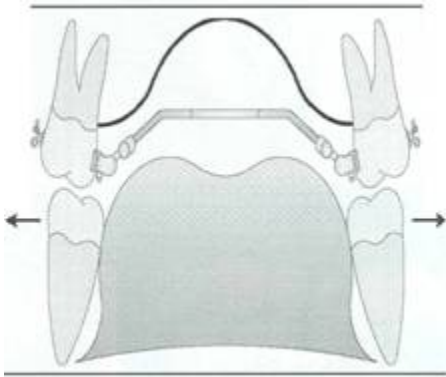


Fig. 21 Lower tongue posture can promote expansion and transverse growth in mandibular arch.

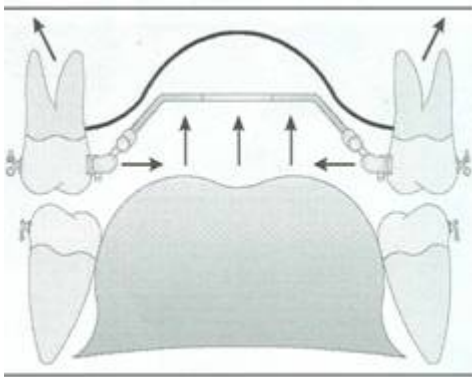


Fig. 22 NPE2 used as stabilizing wire for molar intrusion.

After expansion, the NPE2 can act as a stabilizing wire for molar intrusion (Fig. 22), or provide buccal root torque if the distal end (the wire inserted into the lingual sheath) is torqued with a plier (Fig. 23).

Other specialized uses:

- Unilateral molar correction (Fig. 24)
- Unilateral posterior crossbite correction (Fig. 25)
- Bilateral or unilateral contraction with smaller appliance sizes (Fig. 26)
- Distal rotation and expansion of both the first molars and second bicuspids (Fig. 27)
- Distal rotation and expansion of the molars and second bicuspids, followed by initial cuspid retraction (Fig. 28)

- Leveling, alignment, and rotation of the incisors while the buccal segments are expanded a fixed, three-way sagittal appliance (Fig. 29)
- Leveling, alignment, and rotation of the buccal segments while the molars are expanded and the incisors are retracted (Fig. 30)
- Retention of expansion while the incisors are advanced (Fig. 31)
- Overexpansion of the palatal Nitanium loop in cleft palate cases (Fig. 32)

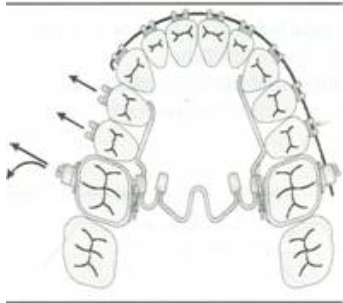


Fig. 24 Unilateral molar correction.

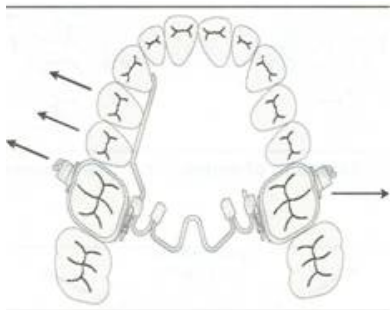

Fig. 25 Unilateral posterior crossbite correction.

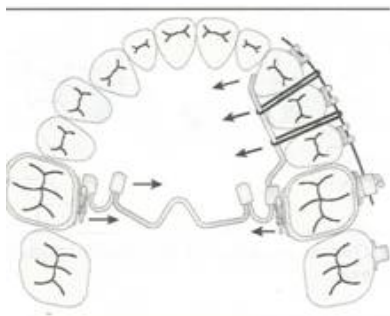


Fig. 26 Bilateral or unilateral contraction with smaller appliance size.

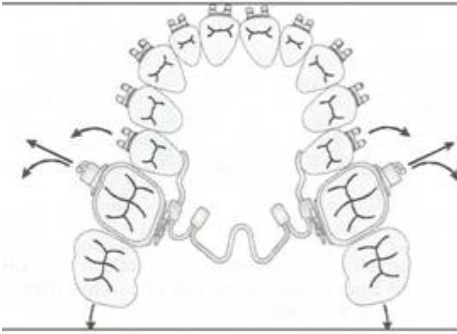


Fig. 27 Distal rotation and expansion of first molars and second bicuspids.

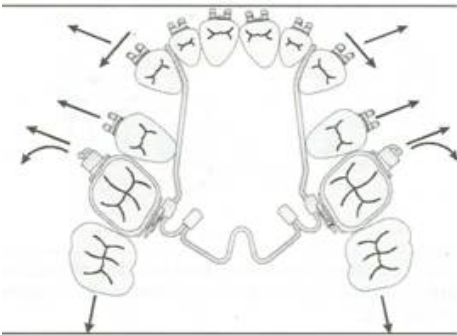


Fig. 28 Distal rotation and expansion of first molars and second bicuspids, followed by initial cuspid retraction.

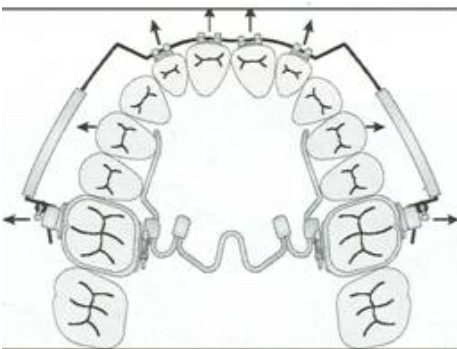


Fig. 29 Leveling, alignment, and rotation of incisors while buccal segments are expanded (fixed, three-way sagittal appliance).

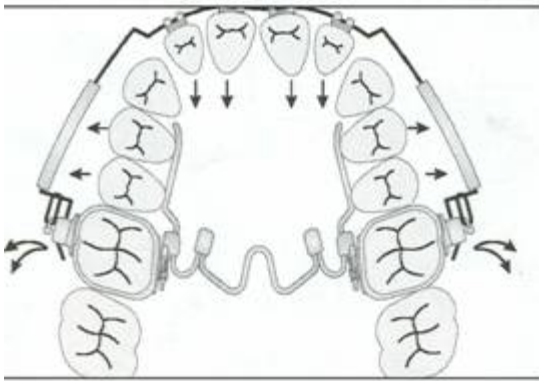


Fig. 30 Leveling, alignment, and rotation of buccal segments while molars are expanded and incisors are retracted.

Conclusion

Advantages of the Nitantium Palatal Expander² over traditional rapid palatal expanders include:

- Better physiologic response and stability
- Preprogrammed to deliver the exact amount of expansion required and to stop at that point
- No severe suture splitting
- Less tipping of abutment teeth
- Can influence the direction of maxillary and mandibular growth
- Rotates molars buccally or distally
- Can be used for anchorage
- Shorter retention period
- Placed at the chair, without laboratory procedures
- Individually adjustable molar loops
- Does not require frequent operator or patient adjustments
- Built-in safety retention system
- Less patient discomfort
- Allows the patient to adjust the wire temperature to mitigate pressure
- Less effect on speech and eating
- Hygienic

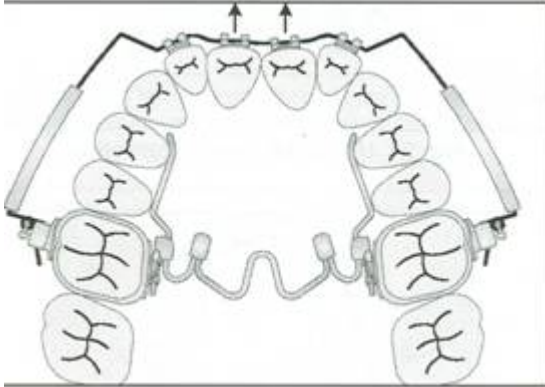


Fig. 31 Retention of expansion while incisors are advanced.

REFERENCES

1. McNamara; J.A. Jr. and Brudon, W.L.: Orthodontic and Orthopedic Treatment in the Mixed Dentition, Needham Press, Ann Arbor, MI, 1995.
2. Ten Hove, A.: Palatal bar and lip bumper in non-extraction treatment, J. Clin. Orthod. 19:272-291, 1985.
3. Haas, A.J.: Rapid expansion of the maxillary dental arch and nasal cavity by opening the mid-palatal suture, Angle Orthod.31:73-90,1961.
4. Haas, A.J.: The treatment of maxillary deficiency by opening the mid-palatal suture, Angle Orthod. 35:200-217, 1965.
5. Haas, A.J. Palatal expansion: Just the beginning of dentofacial orthopedics, Am. J. Orthod. 57:219-255, 1970.
6. Bishara, S.E. and Stanley, R.N.: Maxillary expansion Clinical implications, Am. J. Orthod. 91:3-14,198
7. Hicks, E.P.: Slow maxillary expansion: A clinical study of the skeletal vs. dental response to low magnitude force, Am. J. Orthod. 73:121-141, 1978.
8. Story, E.: Tissue response to the movement of bones, Am. J. Orthod. 64:229-247, 1973.
9. Ekstrom, e.; Henrikson, e.O.; and Jensen, R.: Mineralization in the midpalatal suture after orthodontic expansion, Am. J. Orthod. 71:449-455,1977.
10. McAndrew, J.R.: The continuous force control system, Lancer Technical Report, Lancer Pacific, Carlsbad, CA, 1985.
11. Henry, R.J.: Slow maxillary expansion: A review of quad-helix therapy during the transitional dentition, J.Dent. Child., November-December 1993, pp. 408-413.

12. Bell, R.A. and LeCompte, E.J.: The effects of maxillary expansion using a quad-helix appliance during the deciduous and mixed dentition, Am. J. Orthod. 79:152-161,1981.
13. Bell, R.A.: A review of maxillary expansion in relation to rate of expansion and patient's age, Am. J. Orthod. 81:32-37,1982.
14. Corbett, M.C.: Molar rotation and beyond, J. Clin. Orthod. 30:272-275, 1996.
15. McConnell, T.L. et al.: Maxillary canine impaction in patients with transverse maxillary deficiency, J. Dent. Child., May-June 1996, pp. 190-195.

Ortho Organizers Pty Ltd

PO Box 478
Sylvania Southgate NSW 2224
Australia

1300 ORDERZ

(1300 673 379)

www.naol.com.au

sales@naol.com.au