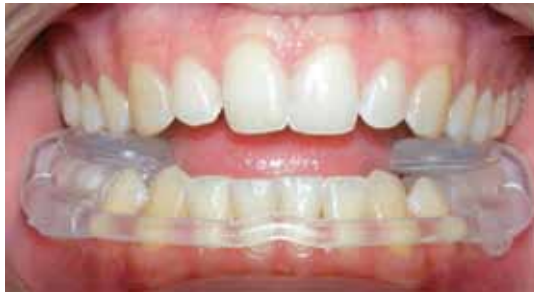

Functional Diagnostics and AquaSplint Therapy

A novel procedure for simple diagnosis and effective therapy of the TMJ/TMD during orthodontic treatment

By **Dr Aladin Sabbagh** (Orthodontist/Oral Surgeon) & **Dr Derek Mahony** (Specialist Orthodontist)



Temporomandibular joint screening prior to orthodontic rehabilitation is indispensable for preventive, therapeutic, and forensic reasons.^[2]

Daily practice calls for a simple and effective concept in order to treat TMD patients, and to avoid iatrogenic mishaps during orthodontic therapy. Furthermore, planning and prognosis may be improved in many cases.

Most diagnostic methods, from expensive axiographic and electromyographic measurement, through to sophisticated imaging techniques (MRI, ct) entail considerable costs in terms of time and expense. As these techniques mostly focus on the examination of special parts and structures, they cannot be considered as universal standard examination methods.

The Manual Functional Analysis according to the Kiel concept (Bumann et al. 1989) provided the first substantial progress towards a practice-oriented concept (Fig. 1)^[2]



Figure 1

On this basis, the AquaSplint concept was developed. In compact form the established techniques of the Kiel concept are utilized for tissue-specific diagnostics^[3,4,5]. Subsequently, TMD etiology and differential diagnosis are determined using the AquaSplint. This significantly affects therapy decisions and treatment planning.

The previous hypothesis implying that temporomandibular joint disorders / TMD originate from the stomatognathic area is only partially correct^[6]. Opinions in the current literature widely differ on this topic. We believe that malocclusion may be among the causes of certain TMJ disorders, however rarely appears to be the only one. As generally known, there are patients who, despite extreme malocclusion, show hardly any, or no TMJ discomfort, while other patients are sometimes severely affected despite minor occlusal discrepancies.

Craniomandibular disorders (TMD) result from an interplay of multiple factors:

- ◆ malocclusion, overloading of the temporomandibular joint (compression, forced position)
- ◆ hyperactivity of masticatory muscles (bruxism/clenching)
- ◆ psychosomatic disorders, stress syndrome
- ◆ joint hypermobility, particularly in combination with general connective tissue weakness (Fig 2, 2a)^[7, 8]
- ◆ trauma

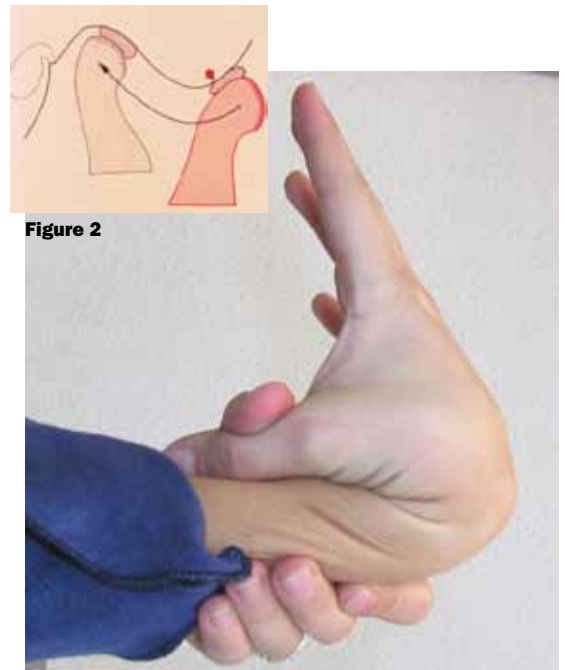


Figure 2

Figure 2a

- ◆ neck disorders / cervical spine syndrome
- ◆ internal diseases (hormonal, circulatory disorders, rheumatism)

TMJ internal derangement results from joint hypermobility rather than from malocclusion. In a 12-year long-term study (1997-2009), by our orthodontic practices, all patients with diagnosed disc displacement (n= 535) were manually examined for their bite position, including the wrist joint. In cases of doubt, magnetic resonance images were obtained. Anterior disc displacement, with reduction, was found in 421 patients, while 114 patients showed displacement without reduction.

The association with connective tissue weakness was highly significant. Concomitant general connective tissue weakness was observed in 92.5 per cent of the patients (Fig 2b). In contrast, no significant association was revealed between malocclusion and the above-mentioned disc disorders.^[9]

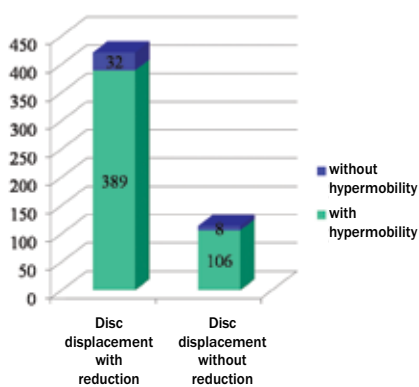


Figure 2b

Therefore, some doubts are raised about the indication of disc repositioning with occlusal rehabilitation. This type of therapy is often complicated, time-consuming and expensive, and not without risk in the case of surgical repositioning. Moreover, this therapy does not necessarily protect from complete disc displacement, without reduction, at a later stage.^[8]

Even when therapy achieved optimum occlusal conditions and complied within narrow limits of indication, there were usually intact posterior ligaments. This is true in partial anterior disc displacement, and the presence of a distal bite in need of treatment.

According to our current AquaSplint concept, clicking alone does not constitute an urgent need for therapy. On the other hand, existing pain symptoms have to be examined as to whether they actually originate from the temporomandibular joint/masticatory muscles. Phantom or referred pain has to be excluded by tissue-specific manual diagnostics. The next diagnostic step should aim to determine

whether malocclusion is the main cause of pain. This is achieved most effectively through (temporary) neutralization / disengagement of the existing malocclusion using the AquaSplint. Thus, a possible forced bite is eliminated and the muscles become relaxed. In more serious cases, manual and physical adjunct therapy should be applied.

A malocclusion-related TMD will usually respond due to AquaSplint therapy within four weeks. Pain relief of at least 50 per cent is a favourable precondition and indicator of promising orthodontic rehabilitation. Use of the AquaSplint often changes the bite. Subsequently, the resulting new and almost painless bite position may require orthodontic rehabilitation, or at least stabilization, by means of an adjusted splint for night time use.^[10]

AquaSplint:

The AquaSplint is a self-adjusting, customisable, pre-fabricated TMD splint which can be inserted immediately without preparations, impressions, or registrations. The device consists of two water pads connected by a tube (hydrostatic aquabalance). The water pads are provided with an acrylic saddle which can be relined with a long-term silicone material. Such individualization enables immediate optimum stability and comfort and, unlike conventional hard bite splints, offers the following advantages:

- ◆ immediate pain relief without laboratory procedures or preparations;
- ◆ universal use and insertable in the patient's mouth, within a few minutes;
- ◆ self-adjusting, no grinding or frequent recall appointments required (thanks to the hydrostatic balance between the two water pads)
- ◆ replaces the relaxation and distraction splint (no increased compression within the joint in contrast to splints with frontal bite plane)
- ◆ high accuracy and comfort of fit through individual relining
- ◆ no more than 10 hours of daily wearing (8 hours by night, 2 hours by day)
- ◆ excellent clinical results and patient satisfaction owing to rapid pain reduction, comfort, and advantageous repositioning of the mandible
- ◆ higher stability and less visibility compared to a maxillary splint

In comparison to similar aqua pads the AquaSplint offers the following advantages:

- ◆ increased muscle relaxation: i.e. conventional products must be held in position by permanent mouth closure or muscular activity, which may interfere with sufficient muscle relaxation. The immanent stability

of the AquaSplints (relining) and the favourable positioning of the mandible enable improved muscle relaxation.

- ◆ the only self-adjusting customisable TMD bite splint applicable even during orthodontic treatment ("prior blocking out of brackets with protection wax") (Fig. 3, 3a)
- ◆ longer life time (4-6 weeks) with hardly any loss of fluid
- ◆ devoid of sharp edges

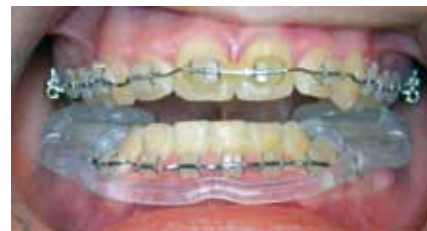

Figure 3

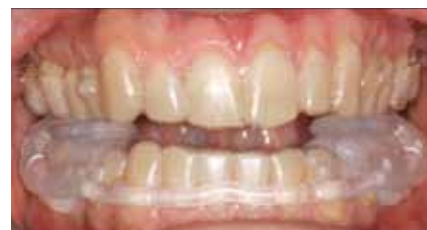

Figure 3a

Indications:

- ◆ Rapid pain relief, particularly in acute cases (e.g., accidents, trauma, and disc displacement, without reduction, associated with markedly limited mouth opening and difficult impression-taking)
- ◆ Muscle relaxation, particularly in cases of acute or intermittent teeth grinding (Bruxism /clenching), e.g. during stress periods such as exams and acute psychological trauma (not suitable for chronic bruxism)
- ◆ Identification and elimination of hidden functional disorders, premature contacts, forced bites
- ◆ Simple pre-prosthetic / pre-orthodontic bite determination
- ◆ High differential diagnostic validity and supportive therapy in associated diseases with multifactorial aetiology (neck disorder syndrome, tinnitus, migraine headache, stress syndrome and sleep apnoea)
- ◆ Adjunct treatment supportive of osteopathic/physical therapy after trauma and surgery

Due to the hydrostatic effect of the two water pads, the jaw position and occlusal contacts become levelled and harmonious, without grinding-in and adjustment (conventional bite splint), i.e. the mandible achieves a self-balanced position.

This new pain-free / pain-reduced therapeutic position provides the basis

for subsequent occlusal rehabilitation (prosthetic in vertical discrepancies, orthodontic in transversal, and sagittal discrepancies).

In addition, the three primary tasks of classic splint therapy are addressed: decoupling of pathological occlusion, tone reduction of hyperactive masticatory muscles, and reduction of enamel abrasion.

Convenient and simple handling

The saddle width can be adjusted, when necessary, through expansion, compression or cutting. This makes the AquaSplint applicable to any tooth shape, crown/bridge, and brackets or bands.

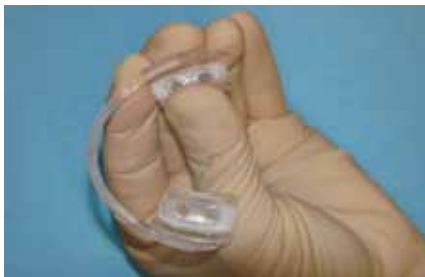

Figure 4

After bonding was applied to the inner surfaces of both saddles

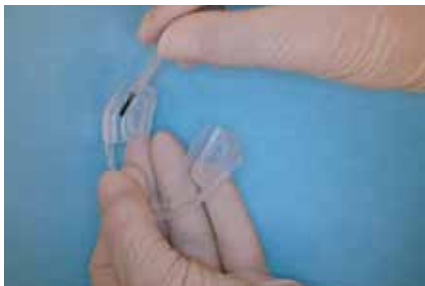

Figure 5

The specially fabricated long-term resilient (soft) relining silicone is briskly sprayed onto the inner surfaces of both saddles with high pressure. Use of a dispenser is recommended due to the shore hardness 60, and in order to ease the working time. (Fig 6, 6a)

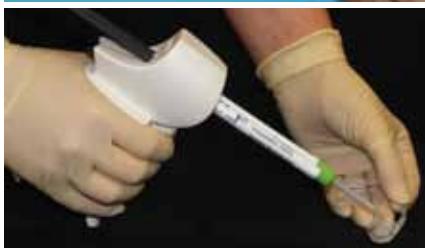
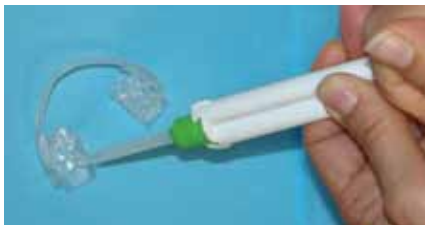
Figure 6 and 6a

Subsequently, the Aqua Splint is inserted in the lower jaw (saddle on 35/36 or 45/46). A reverse "V" marks the middle of the connecting water tube and facilitates accurate positioning between 31, 41. Strong contact between the tube and the gingiva should be avoided. (Fig. 7)

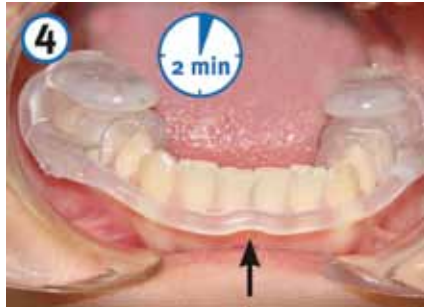

Figure 7

Excess silicone can be removed after 2-3 minutes (Fig. 8)

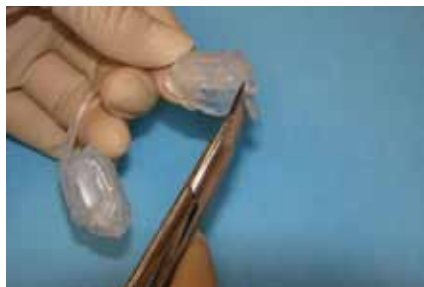

Figure 8

The Aqua Splint can not be used as a permanent splint without an additional 0.5 mm thin stabilizing material (Fig 9), as undesired occlusal alterations/changes cannot be ruled out. The additional 0.5 mm splint has proved a good compromise solution especially for patients who are unable or unwilling to wear a rigid bite splint, after AquaSplint therapy. Furthermore, those additional thin splints clearly prolong the lifetime of the Aquasplint, particularly in bruxism cases. Usually, prosthetic/ orthodontic rehabilitation or an adjusted permanent splint (as a compromise) should follow AquaSplint therapy. If the malocclusion has been the main reason of the pain, and if there is a huge discrepancy between the old and the new therapeutic/painless occlusion, then permanent phase 2 changes are required. In some cases, occlusal rehabilitation is unnecessary, especially if the existing TMD mainly results from trauma or systemic disease rather than from the malocclusion.

Should AquaSplint therapy fail to yield considerable improvement after 4-6 weeks, stomatognathic factors can be ruled out as a main cause of TMD. Unfortunately, such patients cannot be helped in the dental practice, except for abrasion prevention. In these cases, interdisciplinary consultation involving other disciplines such as

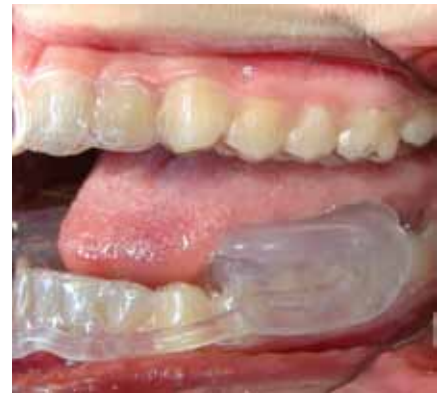

Figure 9

ENT, orthopaedics or psychology is recommended.

Our experience with the AquaSplint concept has shown excellent clinical results and patient satisfaction, particularly due to rapid pain reduction, wear comfort, and favourable repositioning of the mandible. Great advantages for the provider are the simple and quick diagnostic procedure, the effective therapy, and the chance to dispense with impressions, registrations, laboratory procedures and grinding-in of hard splints. The new concept does enable us to provide exact diagnosis, and targeted therapy, at a reasonable time and expense. ♦

References

- [1] ZM 93, Nr.14, 16.7.2003, (1743)
- [2] Bumann, Axel; Lotzmann, Ulrich, TMJ Disorders and Orofacial Pain, 2002. XVII, 360 p. w. 1304 : Thieme, ISBN: 9783131271617
- [3] Sabbagh, A. Kiefergelenkdysfunktion, Teil I, 130-133. ZMK Nr. 3, Spitta Verlag, 2000.
- [4] Sabbagh, A. Kiefergelenkdysfunktion, Teil II, 210-212. ZMK Nr. 4, Spitta Verlag, 2000.
- [5] Sabbagh, A. Kiefergelenkdysfunktion, Teil III, 294-298. ZMK Nr. 5, Spitta Verlag, 2000.
- [6] Madsen, Neues aus der Zahnheilkunde – Blick in die zahnärztliche Literatur. Journal of Orofacial Orthopedics/Fortschritte der Kieferorthopädie 2008; Band 69, Heft 1, S. 1-4
- [7] P.U. Dijkstra1*,2,3,4, T.J.B. Kropmans5, and B. Stegengal, J Dent Res 81(3):158-163, 2002, The Association between Generalized Joint Hypermobility and Temporomandibular Joint Disorders: A Systematic Review
- [8] A.Sabbagh, EOS, Berlin 2007, Poster. Influence of condylar hypermobility on relapse after bite jumping
- [9] A.Sabbagh, Lecture `Die neue Bedeutung der Malloklusion in der multifaktorellen Genese der CMD; at the 43 annual meeting of the german association of functional diagnosis and therapy, DGFDT, Frankfurt, 12.Nov.2010.
- [10] ZMK 10 (25), 700-703 Dr. Aladin Sabbagh, CMD: Das Aqua Splint Konzept

